

Companions to Management Series



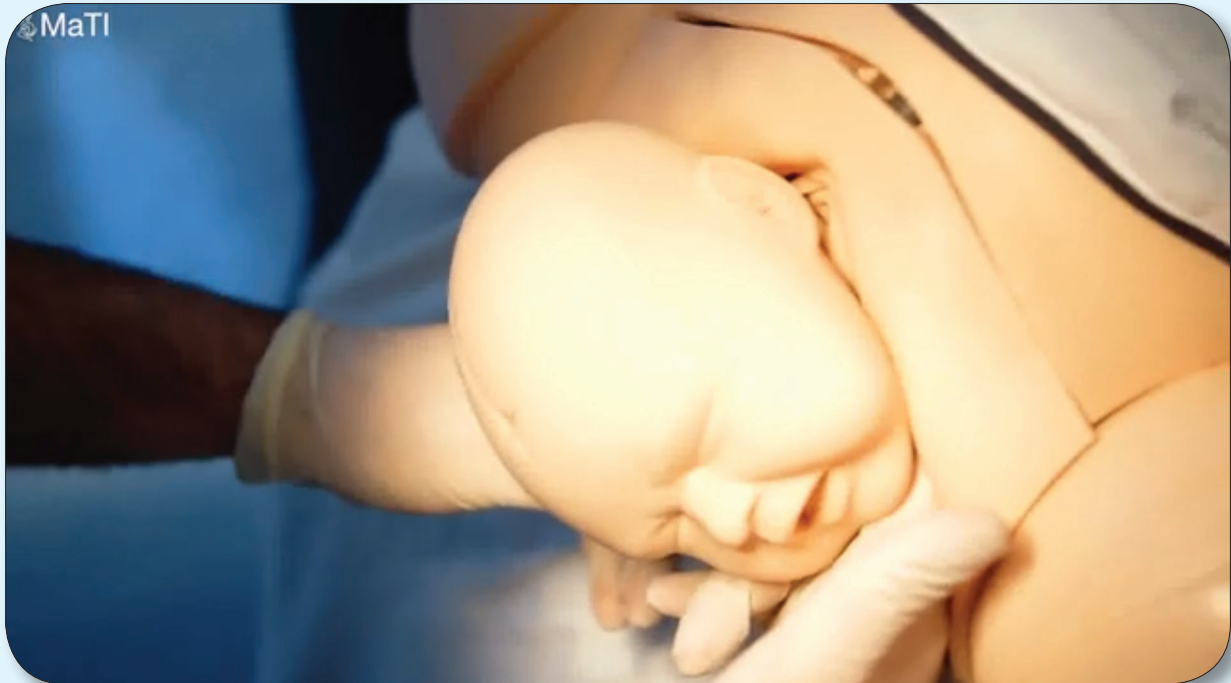
SHOULDER DYSTOCIA

The
Welfare of Women



Shoulder Dystocia

Shoulder dystocia is an obstetric emergency. It occurs when there is delay between delivery of the fetal head and body, usually due to the anterior shoulder becoming impacted behind the pubic symphysis. There are significant risks to both mother and baby and **urgent resolution is essential**.



https://www.glowm.com/resource_type/resource/skills/title/shoulder-dystocia/resource_doc/1535



Clinical Relevance

Shoulder dystocia occurs in 6–7/1000 of vaginal deliveries. Stretching of the nerves in the brachial plexus – which runs anterior to the shoulder and supplies the motor and sensory function of the arm – occurs in 1 in 20 babies.

Although many such injuries resolve in time, some babies may develop permanent damage. The baby is also at risk of brain injury and death if not delivered urgently. There is an increased risk of postpartum haemorrhage (PPH) and perineal tears involving the anal sphincter muscles to the mother, due to the additional manoeuvres which may be required to deliver the shoulders.

Presence of the following risk factors should lead to anticipation of shoulder dystocia. However, many cases of shoulder dystocia do not have pre-existing risk factors, and many other women with risk factors will have uncomplicated deliveries. Shoulder dystocia is often an unanticipated, unpredictable obstetric emergency.

Risk Factors for Shoulder Dystocia	
Antepartum	Intrapartum
• Large baby	• Slow progress in first stage of labour
• Maternal obesity	• Slow progress in second stage of labour
• Diabetes	• Assisted vaginal delivery
• Previous shoulder dystocia	• Induction/augmentation of labour
• Previous large baby	
• Prolonged pregnancy	

Once the fetal head has been delivered, shoulder dystocia can only be diagnosed when the fetal body is not delivered with the next contraction. It is important to allow this time to await normal restitution and completion of delivery, otherwise shoulder dystocia can be incorrectly diagnosed.

Conversely, the time critical nature of management once diagnosis has been made dictates that anticipation of potential issues can limit injury to the baby. Where significant risk factors exist, or clinical signs are suggestive of impending shoulder dystocia, it can be helpful to have support ready and coordinated in case manoeuvres are required – i.e. pre-allocate different roles in the management algorithm (see below) in order that everyone is clear on their task and ready to go if required.

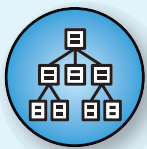
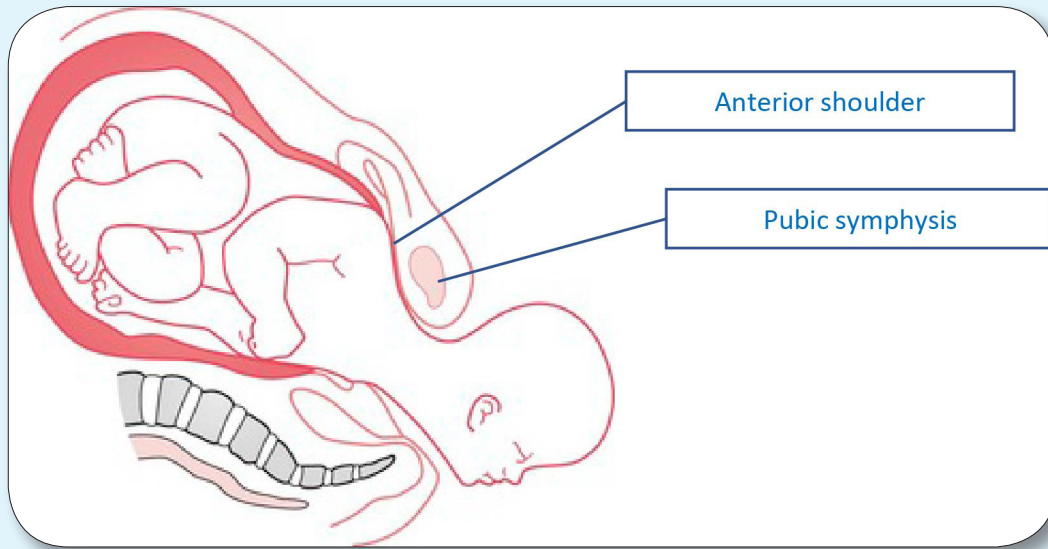
The following features provide an early warning to call for help,

- **Head bobbing:** the head comes down to the perineum on pushing, but disappears again between contractions
- **Turtle sign:** the head is delivered but then pulls tightly back against the perineum
- **Failure of restitution:** after the head delivers it remains looking straight down or up (normally it should turn to face sideways)

After diagnosing shoulder dystocia, it is important not to use excessive traction on the fetal head as this can lead to stretching of the nerves comprising the brachial plexus, leading to injury. Traction on the fetal head should be in line with the axis of the baby – i.e. outwards in a straight line – rather than down towards the floor.

Application of pressure on the fundus of the uterus is dangerous and should be avoided.




Delivery of the trapped shoulders requires either an increase in diameter of the maternal pelvis or a reduction in the width of the fetal shoulders. The manoeuvres described below aim to achieve this.


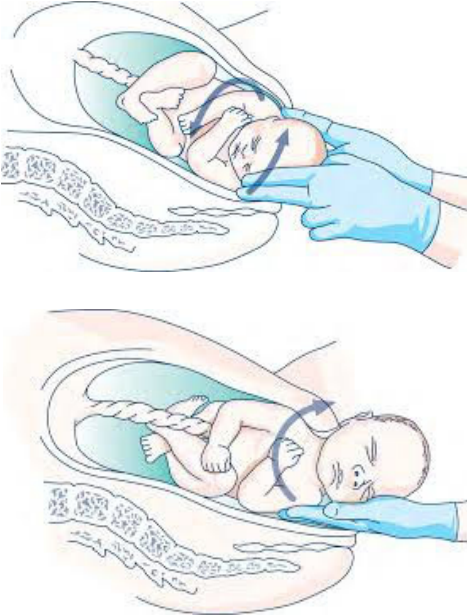


Management Algorithm

The following steps should be undertaken in the order presented as soon as a shoulder dystocia is diagnosed. The baby's condition may deteriorate quickly, so every minute is important. The Maternity team should practice the algorithm regularly together in order to be able to complete it efficiently.

What to do		Description	Reasoning
Call for Help		Call for the immediate support of available team members When they arrive, explain clearly that this situation involves a shoulder dystocia	It is helpful to have assistance with the following manoeuvres, plus any potential neonatal resuscitation or PPH management
Lie the patient flat (remove any pillows) and ask her not to push further, as to do so risks pressing the baby's shoulder harder against the pubic bone.			

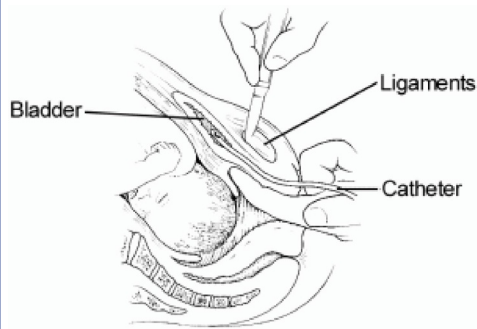
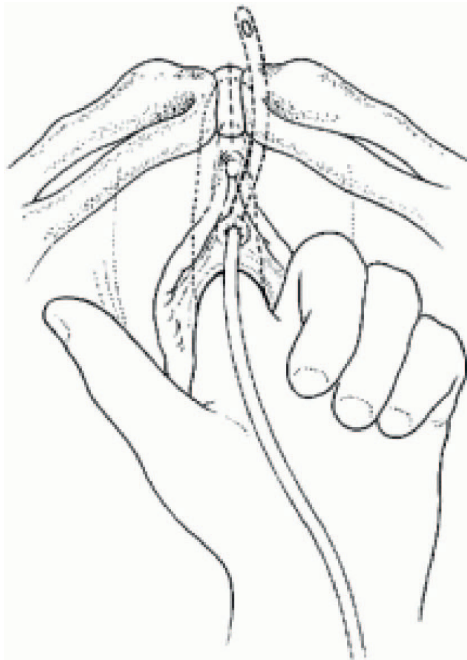
<p>Legs</p> <p>McRobert's Manoeuvre + Moderate axial traction on the fetal head (for 30 seconds)</p>	 <p>Images from https://www.ambulance.qld.gov.au/docs/clinical/cpp/PPP_Shoulder%20dystocia.pdf</p>	<p>Ask the woman to lie on her back, initially straighten her legs, then hold them tightly against her chest with hips flexed and knees wide apart</p> <p>This is called 'McRobert's Manoeuvre'</p> <p>Other Maternity team members (or a birth companion) can help hold the legs in position</p>	<p>This increases the diameter of the maternal pelvis</p>
<p>Suprapubic pressure</p> <p>+ Moderate traction on the fetal head + McRobert's Manoeuvre (for 30 seconds)</p>		<p>Ask an assistant to stand on the same side of the mother as the baby's back and apply continuous pressure on the abdomen <u>just above</u> the pubic symphysis (not on the pubic bone itself)</p> <p>Use the heel of the hand to do this, with both hands inter-connected</p>	<p>This reduces the diameter of the baby's shoulders and can dislodge the anterior shoulder from underneath the pubic bone</p>
<p>Roll the patient into an 'all fours' position + Moderate traction on the fetal head (for 30 seconds)</p>		<p>Encourage the patient to move onto her hands and knees</p>	<p>Kneeling on all-fours increases the diameter of the pelvis</p>

<p>Deliver the posterior arm + McRobert's Manoeuvre (for 30 seconds)</p>		<p>Introduce one hand along the posterior wall of the vagina and attempt to reach the baby's wrist</p> <p>Sweep this down and out of the vagina, then deliver the rest of the body as normal</p> <p>Aim to enter the vagina posteriorly as this is where there is most space</p> <p>An episiotomy can help improve access further (but will not solely facilitate delivery, as the baby is trapped by the bone, not the soft tissues of the perineum)</p>	<p>This reduces the width of the baby's shoulders</p>
<p>Internal rotation of the baby + McRobert's Manoeuvre (for 30 seconds)</p>		<p>Insert one hand into the vagina – start posteriorly and then move first and second fingers up to sit behind the anterior shoulder</p> <p>Apply pressure with the fingers onto the anterior shoulder and attempt to rotate this forward</p> <p>A second hand can be placed on the front of the posterior shoulder</p> <p>If unsuccessful, move the top hand down and the bottom hand up, and attempt to rotate in the opposite direction</p>	<p>This dislodges the impacted shoulder from behind the pubic symphysis</p>
<p>Repeat all the previous steps in the same order. Consider changing practitioners, if other trained colleagues are available, as sometimes a new person's perspective can help. Normally the baby will deliver with some combination of these manoeuvres.</p>			

Symphysiotomy

This procedure can lead to long-term complications for the patient, so **should only be considered as a last resort** if the previous steps have been unsuccessful.

Symphysiotomy is not a recommended option in centres where ready recourse to an emergency caesarean section is available.



https://hetv.org/resources/reproductive-health/impac/Procedures/Symphysiotomy_P53_P56.html

It is essential that the mother's **legs are supported** in the **lithotomy** position – with one person supporting each leg

Inject local anaesthetic into the skin and pubic symphysis

Insert a **urinary catheter** and use the left index finger in the vagina to displace the catheter to one side

Apply antiseptic solution to the skin

Cut down with a scalpel through the skin in the midline into the centre of the pubic symphysis until the pressure of the blade is felt near the middle finger in the vagina

Cut the lower half of the pubic symphysis, remove the blade, turn it round and cut the upper half

Pinch between the finger in the vagina and the thumb on top of the pubic symphysis to open it up.

Remove the catheter

Undertake an **episiotomy** and attempt delivery of the baby

This allows the pelvis to open further, but in doing so can make it unstable

After delivery:
Compress the symphysis between finger and thumb for 5 minutes

Catheter for 5 days

Apply elastic strapping from one iliac crest to the other

Bed rest for 3 days with knees loosely strapped together..

Refer urgently to hospital

If these manoeuvres are unsuccessful then immediate transfer to a higher-level health centre should take place. However, given the time critical nature of such a delivery, it is likely that the baby will not survive.

Additional Management	<p>Anticipate a post-partum haemorrhage (PPH) and manage this appropriately</p> <p>Assess for injury to the anal sphincter (3rd or 4th degree tear) and undertake appropriate repair of any perineal trauma</p> <p>Debrief the patient and her birth partner, as this can be a stressful situation for them</p> <p>Careful monitoring of the baby, including a full neurological assessment</p>
------------------------------	---



Associated GLOWM Resources

- Skills video on managing shoulder dystocia
https://www.glowm.com/resource_type/resource/skills/title/shoulder-dystocia/resource_doc/1535

References

Managing Obstetric Emergencies and Trauma. The MOET course manual. 3rd Edition. Edited by S Paterson-Brown & C Howell. Cambridge University Press. 2014. <https://extranet.who.int/rhl/resources/videos/steps-overcome-shoulder-dystocia>

This Companion to Management has been developed and written by
James Phillips MRCOG
Chelsea & Westminster Hospital NHS Foundation Trust, London, UK

General Series Editor for this programme
John Heathcote MRCOG
Oxford University Hospitals, UK